

See discussions, stats, and author profiles for this publication at: <https://www.researchgate.net/publication/340684122>

Z-POEM (Per Oral Endoscopic Myotomy) for the management of large Zenker's diverticulum

Article in *Acta gastro-enterologica Belgica* · April 2020

CITATIONS

2

READS

133

3 authors, including:



Shaimaa Elkholy
Cairo University

88 PUBLICATIONS 344 CITATIONS

SEE PROFILE



Ahmed Mohamed El-Sherbiny
Ain Shams University

56 PUBLICATIONS 133 CITATIONS

SEE PROFILE

Z-POEM (Per Oral Endoscopic Myotomy) for the management of large Zenker's diverticulum

S. Elkholy, K. Essam, M. El-Sherbiny

Gastroenterology Division, Internal Medicine Department, Faculty of Medicine, Cairo University, Egypt.

To the Editor,

Zenker's diverticulum is a rare disorder characterized by herniation of the post pharyngeal wall through Killan's triangle (between the inferior constrictor muscle and cricopharyngeus muscle) (1). It occurs most commonly in males and elderly people. The exact etiology is unknown, however its postulated that its due to increased intraesophageal pressures together with spasm in the cricopharyngeus muscle (1). So, the treatment modalities were directed into cutting the cricopharyngeus (septum). Surgical intervention had been the current stay of treatment despite its relatively high related morbidity and mortality (2). Endoscopic intervention had aroused aiming into cutting the septum, but it carries the risk of perforation and incomplete cutting of the septum which comprises higher recurrence rates (3). In the past couple of years there had been sporadic reported cases in managing Zenker's diverticulum by Per oral endoscopic myotomy (POEM) (4). POEM was first introduced by Prof.Inoue in japan 2010, which is based on the idea of tunneling or so called 3rd space endoscopy (5). The application of POEM had expanded lately to solve some

tunneling endoscopic resection). Here we present the novel approach to Zenker's diverticulum that had been tried recently in the last few years (Z-POEM).

Our patient is an elderly 74-year-old male who had been suffering from regurgitation, dysphagia and recurrent attacks of choking for 2 years. Imaging studies and endoscopy proved the diagnosis of large (> 6cm) Zenker's diverticulum. After discussing the treatment options with the patient, we proceeded for Z-POEM. The procedure was done under general anesthesia, using therapeutic Endoscope (GIF; H190, Olympus, Tokyo, Japan) with working channel of 3.7mm. A hybrid knife T-type connected to a VIO 3 electrosurgical unit was used (Erbe Elektromedizin GmbH, Tübingen, Germany) with settings of Endo cut Q (duration 3, effect 3) and soft coagulation (effect 4.5, 60 watt). As shown in figure (1) the steps started with opening a tunnel just proximal to the septum. Then submucosal dissection was done on both sides of the septum (the diverticular side and the esophageal side). After reaching the base of the septum cutting of the septum was done using IT knife till reaching the base. Extended myotomy in the esophageal muscles was done up to 2 cm. Afterwards, there was marked

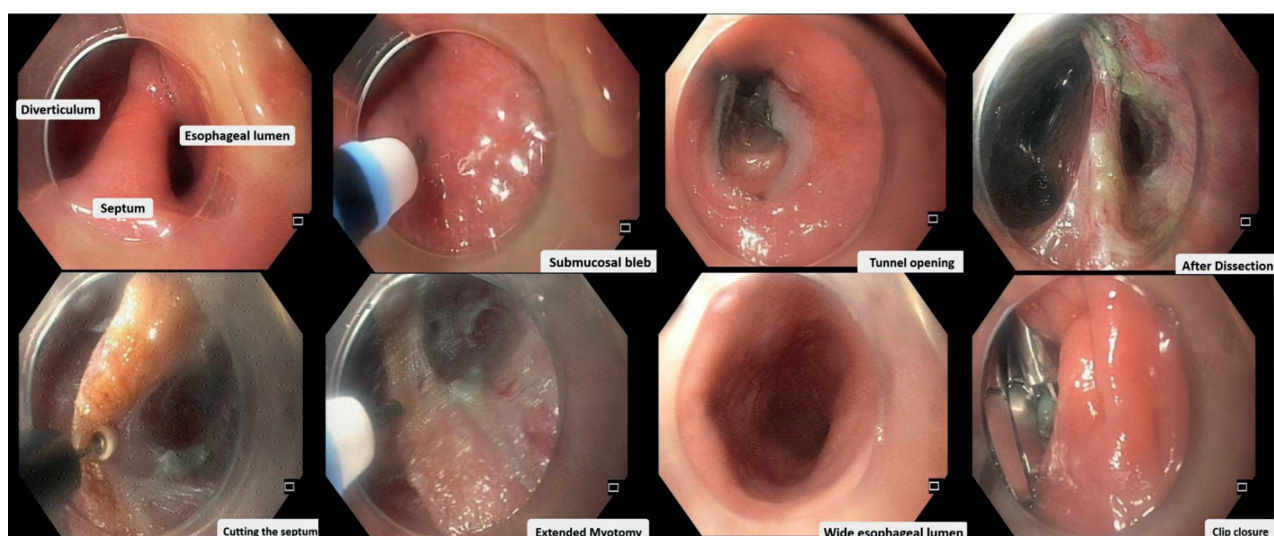


Figure 1.

other gastrointestinal conditions other than achalasia. It had been applied for relieving pylorospasm in G-POEM (gastric POEM). It had also been extended to the removal of submucosal tumors through STER (submucosal

Correspondence to : Shaimaa Elkholy, Kasralainy street, 00202 Cairo, Egypt.
E-mail : shuma50082@gmail.com

Submission date : 31/08/2019

Acceptance date : 06/09/2019

relief of the upper esophageal spasm with widening of the esophageal lumen. Then the opening of the tunnel was closed with 5 hemoclips. The procedure took 115 minutes without complications, and the patients' symptoms markedly improved after.

We believe that Z-POEM is a genius solution that solved the drawbacks of both surgical and conventional endoscopic intervention. Its not a dramatic procedure as surgery with expected lower morbidity and mortality, taking into consideration that Zenker's diverticulum is usually in elderly people (7th-8th decade) with associated comorbidities. It enables better visualization of the septum and reaching till its end than the conventional diverticulectomy, so less recurrence rate. Besides the risk of perforation is nil due to tunneling. It's also postulated that extended myotomy of the esophageal muscles can lower the recurrence rate which can be achieved through Z-POEM (6).

Randomized control trials are needed for approving the efficacy and safety of Z-POEM in comparison to other therapeutic interventions.

References

1. FERREIRA LE, SIMMONS DT, BARON TH. Zenker's diverticula: pathophysiology, clinical presentation, and flexible endoscopic management. *Dis Esophagus*, 2008, **21** : 1-8.
2. DZELETOVIC I, EKBOM DC, BARON TH. Flexible endoscopic and surgical management of Zenker's diverticulum. *Expert Rev Gastroenterol Hepatol.*, 2012, **6** : 449-65 ; quiz 466.
3. CHANG CY, PAYYAPILLI RJ, SCHER RL. Endoscopic staple diverticulostomy for Zenker's diverticulum: review of literature and experience in 159 consecutive cases. *Laryngoscope*, 2003, **113** : 957-65.
4. HAJIFATHALIAN K, DAWOD Q, SAUMOY M, *et al.* Submucosal tunneling endoscopic septum division for treatment of Zenker's diverticulum. *Endoscopy*, 2018, **50** : E340-1.
5. INOUE H., MINAMI H., KOBAYASHI Y., SATO Y., KAGAM., SUZUKI M., *et al.* Kudo. Peroral endoscopic myotomy (POEM) for esophageal achalasia. *Endoscopy*, 2010, **42** : 265-271.
6. BIZZOTTO A, IACOPINI F, LANDI R, COSTAMAGNA G. Zenker's diverticulum : exploring treatment options. *Acta Otorhinolaryngol Ital.*, 2013, **33**(4) : 219-229.