

See discussions, stats, and author profiles for this publication at: <https://www.researchgate.net/publication/352957155>

Peroral endoscopic myotomy (POEM) for the treatment of achalasia: A multicenter Middle Eastern experience

Article in Saudi Journal of Gastroenterology · July 2021

DOI: 10.4103/sjg.sjg_49_21

CITATIONS

6

READS

69

20 authors, including:



Abed Allehibi

King Fahad Medical City

75 PUBLICATIONS 785 CITATIONS

SEE PROFILE



Shaimaa Elkholy

Cairo University

88 PUBLICATIONS 344 CITATIONS

SEE PROFILE



Mohamed Guda

21 PUBLICATIONS 190 CITATIONS

SEE PROFILE



Areej Al Balkhi

King Fahad Medical City

19 PUBLICATIONS 368 CITATIONS

SEE PROFILE

Peroral endoscopic myotomy (POEM) for the treatment of achalasia: A multicenter Middle Eastern experience

Abed Al Lehibi¹, Shaimaa Elkholy², Mohamed Gouda³, Ammar Al Dabbagh¹, Areej Al Balkhi¹, Abdullah Almtawa¹, Nawwaf Al Otaibi¹, Mohammed El-Sherbiny², Kareem Essam², Mohammed Attieh Alzahrani^{4,5}, Ahmed Al Ghamdi¹, Adel Al Ghamdi¹, Ahmad AlEid¹, Adel Qutub¹, Abdulrahman Alamr¹, Shameem Ahmad¹, Khalid Al Sayari¹, Bashaar Al Ibrahim¹, Abdullah Al Khathlan¹, Resheed Eid Alkhiari^{1,6}

¹Department of Gastroenterology and Hepatology, King Fahad Medical City, Riyadh, ³Department of Internal Medicine, Gastroenterology, Mouwasat Hospital Dammam, ⁴College of Medicine, King Khalid University, ⁵Gastroenterology Division, Department of Internal Medicine, Asir Central Hospital, Abha, ⁶College of Medicine, Qassim University, Buraydah, Saudi Arabia, ²Gastroenterology Division, Department of Internal Medicine, Faculty of Medicine, Cairo University, Cairo, Egypt

Abstract

Background: Peroral endoscopic myotomy (POEM) was proposed in 2010 as a minimally invasive procedure for the treatment of achalasia. In this article, we describe the Middle Eastern experience with the procedure in terms of efficacy, length of admission, and short- and long-term complications.

Methods: A retrospective analysis of our prospectively collected data on patients who underwent a POEM procedure was conducted between March 2019 and May 2020. The primary outcome was clinical success rate, defined as a postprocedure Eckardt score ≤ 3 at ≥ 3 months. Secondary outcomes included the length of hospital stay, presence of reflux symptoms or need for proton pump inhibitors (PPIs) ≥ 3 months, and adverse events.

Results: During the study period, 67 patients (35 females) underwent the procedure for achalasia. The participants' ages ranged from 11 to 80 years (mean 41 ± 18 years). Eckardt scores before the treatment ranged between 4 and 12 (mean 8.85 ± 1.75). Sixty-four patients (95.5%) achieved Eckardt scores of ≤ 3 at ≥ 3 months after the procedure (95% confidence interval [CI]: 91%–100%). The difference between pre- and post-procedural Eckardt scores averaged around -8 points (95% CI: -7.5 to -8.5 $P < 0.0001$). Adverse events were reported in 24 patients (35.8%) and included pneumoperitoneum (32.8%), reflux symptoms at 3 months (29.9%), and surgical emphysema (3%). Six patients had adverse events that led to prolongation of admission; 3% of whom had aspiration pneumonia, 3% had pneumoperitoneum, 1.5% had both, and 1.5% had an esophageal tear.

Conclusions: POEM is a promising procedure for the treatment of achalasia with a high clinical success rate, short hospital admission, and a reassuring safety profile.

Keywords: Achalasia, Middle East, Peroral endoscopic myotomy (POEM), surgical myotomy

Address for correspondence: Dr. Abed Al Lehibi, Department of Gastroenterology and Hepatology, King Fahad Medical City, P.O. Box 59046, Riyadh - 11525, Kingdom of Saudi Arabia.

E-mail: aallehibi@kfmc.med.sa

Submitted: 28-Jan-2021 **Revised:** 04-Apr-2021 **Accepted:** 06-Apr-2021 **Published:** 02-Jul-2021

Access this article online	
Quick Response Code:	Website: www.saudijgastro.com
	DOI: 10.4103/sjg.sjg_49_21

This is an open access journal, and articles are distributed under the terms of the Creative Commons Attribution-NonCommercial-ShareAlike 4.0 License, which allows others to remix, tweak, and build upon the work non-commercially, as long as appropriate credit is given and the new creations are licensed under the identical terms.

For reprints contact: WKHLRPMedknow_reprints@wolterskluwer.com

How to cite this article: Al Lehibi A, Elkholy S, Gouda M, Al Dabbagh A, Al Balkhi A, Almtawa A, *et al.* Peroral endoscopic myotomy (POEM) for the treatment of achalasia: A multicenter Middle Eastern experience. Saudi J Gastroenterol 2022;28:74-9.

INTRODUCTION

Achalasia is an esophageal motility disorder characterized by impaired relaxation of the lower esophageal sphincter (LES) due to the absence of enteric neurons.^[1] Although global epidemiologic data on achalasia are lacking, it is regarded as an uncommon disorder with a seemingly steady incidence of 1.6/100,000 per year and a rising prevalence that is currently estimated to be around 10 patients/100,000 individuals.^[2,3]

In terms of management, the main goal of the current therapeutic modalities is to lower the pressure of the LES.^[4] The first described therapeutic intervention dates back to the 17th century (by Sir Thomas Willis) and consisted of passing a long, thin whalebone with an attached sponge through the lower esophagus.^[5] Management techniques have been significantly refined afterwards and ranged between conservative pharmacotherapeutic options (e.g., calcium channel blockers), endoscopic options (e.g., pneumatic dilatation [PD], botulinum toxin injections), and surgical techniques (laparoscopic Heller's myotomy [LHM]).^[6] However, each of these modalities has its disadvantages. For instance, symptom recurrence and gastroesophageal reflux (GER) have been described in association with pneumatic dilatation. Similarly, surgical myotomy usually involves a gastric fundoplication procedure to prevent GER. The effects of botulinum toxin injections also tend to be short lived, and the cost is an added disadvantage.^[4,6]

Given the shortcomings of the aforementioned interventions, peroral endoscopic myotomy (POEM) was proposed in the late 2000s as a minimally invasive procedure for the treatment of achalasia.^[5] In 2010, one of the first case series of the procedure was published and consisted of 17 patients showing marked improvements in dysphagia symptom scores.^[7] Since then, multiple studies have demonstrated similar outcomes in terms of efficacy.^[4] Additionally, a number of papers have been published on POEM's efficacy and safety profile in special cohorts such as patients with failed previous laparotomy, LHM, or PD; patients with sigmoid esophagus; pediatrics; and those with spastic esophageal disorders (SEDs).^[8]

In this article, we describe the effects of POEM in patients with achalasia at multiple Middle Eastern centers. We analyzed the data from three tertiary care hospitals in Saudi Arabia and Egypt and present the outcomes of the procedure in terms of efficacy, length of hospital stay, and short and long-term adverse events.

PATIENTS AND METHODS

This article is a retrospective analysis of prospectively collected data on patients who underwent a POEM procedure in any of the three centers included in the study. The recruitment period extended between March 2019 and May 2020. The sample consisted of 67 consecutive patients and included all cases (1) with an established diagnosis of achalasia (using high-resolution esophageal manometry) regardless of the type, duration of symptoms, or previous attempted interventions for treatment and (2) who underwent the procedure during the aforementioned recruitment period. Collected data included demographic characteristics (age and gender), type of achalasia, duration of symptoms, previous therapeutic interventions, length of hospital admission, pre- and post-treatment Eckardt scores, and adverse events within 3 months.

The patients were started on a liquid diet for 2 to 3 days and were kept nil per os (NPO) for 24 hours before the procedure. Prophylactic antibiotics, antiemetics, and proton pump inhibitors (PPIs) were also administered the day before POEM. All procedures were done under general anesthesia with the patients in supine position. In the beginning, esophagogastroduodenoscopy (EGD) was done to identify the key anatomical landmarks. The Z-line (gastroesophageal junction) was identified first; then, 10 cm above the landmark, a mixture of normal saline and methylene blue was injected into the submucosal space. Once done, a 1-cm incision was made in the mucosal lining using the HybridKnife® T-type (Erbe USA Inc., Marietta, GA, USA), followed by creating a submucosal tunnel with the dissection and coagulation features of the HybridKnife®. The tunnel extended to 2 cm below the cardia and was followed by the myotomy portion of the procedure. ENDO CUT® Q, Effect 3, Cutting Duration 2 and Interval 4 were used to perform the myotomy. The cuts were started 1 to 2 cms below the mucosal opening and extended into the cardia based on the subtype of achalasia. The myotomy length ranged between 7 and 10 cm for Types I and II and was calibrated based on manometry for Type III, mostly extending up to 12 cm. The tunnel was then washed with 20 mL of gentamycin, and five to seven hemostatic clips were placed to close the mucosal incision. The steps of the procedure are shown in Figure 1.

The patients were kept NPO (nothing by mouth) and given an intravenous PPI for 24 hours after the procedure, and barium swallow was performed the next day for follow-up. Clear liquids were then initiated for 3 days, followed by a regular liquid diet for 7 days, and a normal diet afterwards.

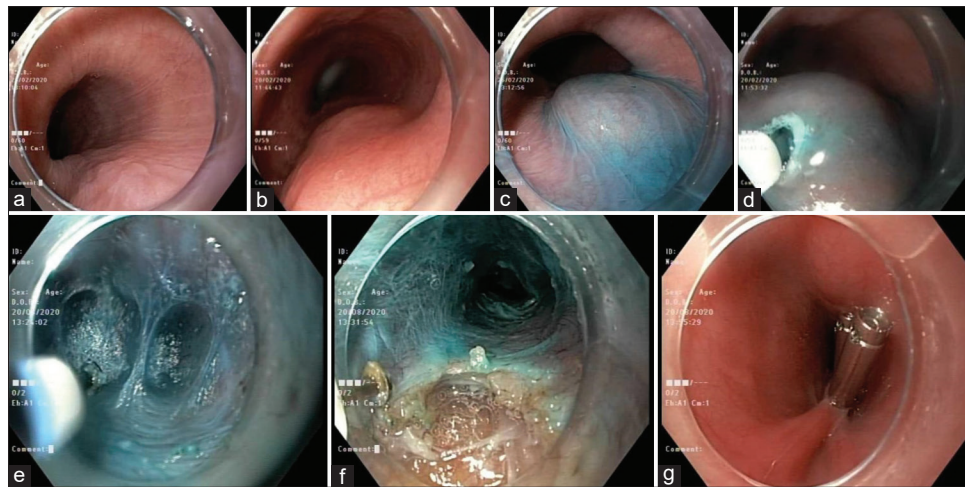


Figure 1: Steps of peroral endoscopic myotomy. (a and b) Esophageal mucosa before the intervention, (c) mucosal elevation and injection with methylene blue, (d) mucosal incision 10 cm above the gastroesophageal junction, (e) submucosal tunneling with the coagulation knife, (f) myotomy using the HybridKnife®, and (g) mucosal closure with hemostatic clips

The patients were discharged on oral PPIs, antiemetics, and pain medications as needed. Follow-up appointments were scheduled at 1 week, 1 month, and 3 months after POEM.

The primary outcome of interest was the clinical success rate, which was defined as a postprocedure Eckardt score ≤ 3 at ≥ 3 months. Eckardt score is a validated, questionnaire-based tool to evaluate the severity of achalasia symptoms. It combines the four main components of achalasia; namely, dysphagia, chest pain, weight loss, and regurgitation. Each component can be given a score from 0 to 3, with higher scores suggesting more severe symptoms.^[9] The final score is calculated by summing the scores of the four components, making the maximum possible score of 12 points. Accordingly, Eckardt symptom scores of 3 or less were regarded as a favorable outcome. The questionnaire was administered in Arabic during the baseline and post-treatment clinical evaluations of the patients.

The secondary outcomes included the length of hospital stay, presence of reflux symptoms ≥ 3 months, need for PPIs ≥ 3 months, and adverse events. The latter were reported according to the latest version of the Common Terminology Criteria for Adverse Events (CTCAE Version 5.0).^[10] Mild to moderate complications that did not require invasive interventions or prolongation of hospital stay were classified as Grades 1 and 2, respectively, whereas severe complications that required an invasive intervention or prolongation of hospital stay were reported as Grade 3. Adverse events that were associated with life-threatening consequences or required urgent intervention were classified as Grade 4, and those resulting in death were classified as Grade 5.

Statistical analysis

Data were analyzed using the IBM SPSS Statistics 26 package. Dichotomous and categorical variables were presented as frequencies and percentages, whereas continuous variables were shown as means \pm standard deviations (*SD*) or medians. The 95% confidence intervals (*CI*) were also reported where appropriate. Pre- and post-POEM Eckardt scores were compared using Wilcoxon signed-rank test. Two-tailed *P* values were reported and were considered significant if $< .05$.

RESULTS

Between March 2019 and May 2020, 67 patients (35 females) underwent the procedure for achalasia. The ages of the participants ranged between 11 and 80 years (mean \pm standard deviation [*SD*], 41 ± 18 years), and the duration of symptoms ranged between 8 months and 16 years. Of the 67 patients who were included, 33 (49%) had classic Type I achalasia, 26 (39%) had Type II achalasia, 4 (6%) had spastic achalasia (Type III), while the remaining (6%) were unclassified. Therapeutic interventions or medical treatment prior to POEM were sought by 25 patients (37%); 24 (35%) had previous PD procedures, 3 (4.5%) had surgical myotomies, and 3 (4.5%) were started on medical treatment. The descriptive statistics (clinical and demographic characteristics) of our patients are shown in Table 1.

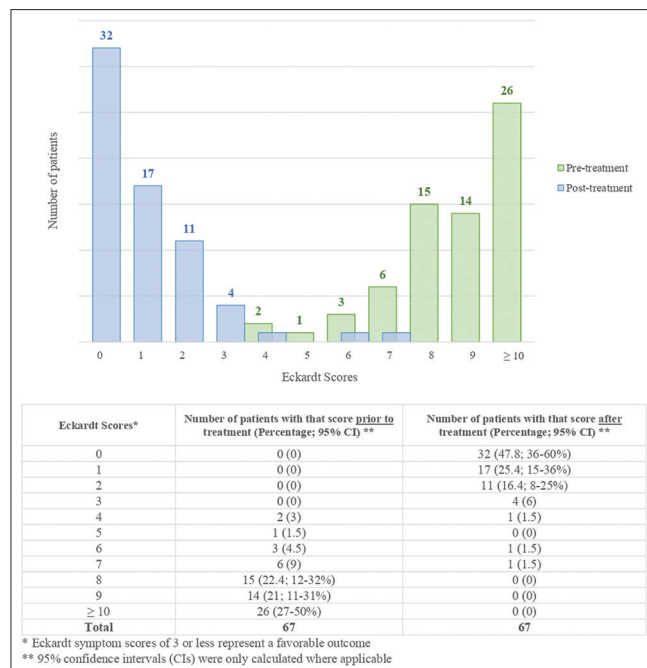
The POEM procedure was completed successfully in all patients, and the length of admission ranged between 2 and 10 days (median of 3 days). Pretreatment Eckardt scores ranged between 4 and 12 points (mean \pm *SD*, 8.85 ± 1.75). Three months after the procedure, 64 patients (95.5%)

Table 1: Patients' characteristics

Variable	Result
Number of patients (n)	67 (35 women)
Age (range in years) [mean, SD]	11-80 [41, 18]
Duration of symptoms (years) [mean, SD]	0.67-16 [3.96, 3.59]
Type of achalasia (n, %)	Type I (33, 49%) Type II (26, 39%) Type III (4, 6%) Unclassified (4, 6%)
Patients who had previous treatments (n, %)	Pneumatic dilation (24, 35%) Surgical myotomy (3, 4.5%) Conservative management (3, 4.5%)

achieved Eckardt scores of ≤ 3 (95% CI: 91%–100%). Score reductions ranged between 3 and 12 points, with a mean of 7.85 ± 2.36 points. Comparison between pre- and post-procedural Eckardt scores showed a statistically significant difference of -8 points (95% CI: -7.5 to -8.5 ; $P < 0.0001$). Figure 2 depicts the aforementioned changes in the primary outcome.

With regard to adverse events, 43 patients (64.2%; 95% CI: 53%–76%) had no immediate complications. Pneumoperitoneum that did not require prolonged hospitalization (>3 days) or invasive intervention (Grade 2 adverse event) was the most commonly found complication (32.8%; 95% CI: 22%–44%) in the remainder of patients. Another Grade 2 adverse event that was found in this series was surgical emphysema, which was reported in 2 patients (3%). Six patients had adverse events that led to prolongation of hospital stay (Grade 3); two (3%) had aspiration pneumonia, two (3%) had

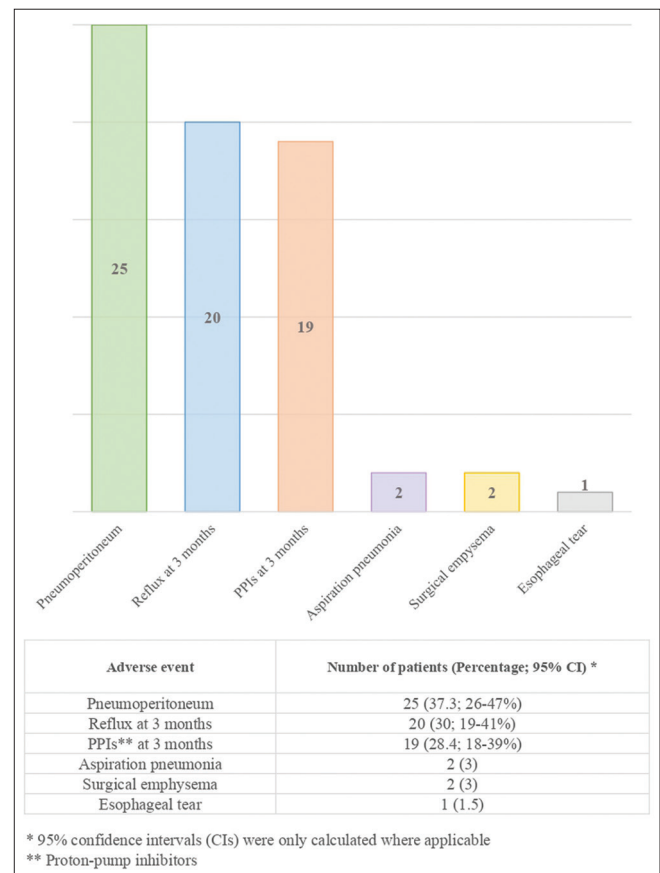

Figure 2: Changes in Eckardt scores before and after the procedure

pneumoperitoneum, one (1.5%) had both, and one (1.5%) had an esophageal tear. With regard to long-term adverse events, 20 patients (29.9%) were found to have symptoms of gastroesophageal reflux ≥ 3 months, 19 (28%) of whom needed to be started on PPIs for symptom control. Figure 3 shows the rate of reported adverse events in our series.

In summary, this series demonstrates that POEM has a clinical success rate of $>95\%$ in patients of achalasia. The procedure requires a relatively short hospital stay (average of 3 days), and has a reassuring safety profile with 91% of patients having no or mild to moderate adverse events, and the remaining 9% having no life-threatening complications or deaths.

DISCUSSION

This was a retrospective analysis of our prospectively collected data on a series of achalasia patients who underwent a POEM procedure between 2019 and 2020. The primary outcome was the reduction in Eckardt scores to ≤ 3 at ≥ 3 months, whereas the secondary outcomes included the length of hospital stay, and short- and long-term adverse events, including the presence of reflux symptoms and need for PPIs ≥ 3 months. Our experience


Figure 3: Reported adverse events

demonstrated a 96% clinical success rate with regard to the primary outcome and a reassuring safety profile with only 9% of patients requiring prolongation of their hospital stay due to adverse events.

The first published paper on the utility of POEM included an experimental, porcine model in 1980.^[11] In 2010, Inoue *et al.*^[7] published a refined version of the procedure and proposed it as a novel alternative for the treatment of achalasia. Before the emergence of the technique, other treatment modalities were in vogue. Some approaches were conservative and involved the use of pressure-lowering medications such as calcium channel antagonists and nitrates, whereas others directly targeted the LES by means of endoscopic pneumatic dilatation, injection of botulinum toxin, or Heller's myotomy.^[4] Although proven effective, these modalities had drawbacks. For example, pneumatic dilatation, which is the most commonly performed intervention, like POEM, is minimally invasive, but it has a high risk of symptom recurrence and postprocedure GER. Botulinum toxin injection is another minimally invasive procedure and can be performed under endoscopic vision, but it has a short-term therapeutic effect, requires repeated procedures, and can incur a high treatment cost. Surgical myotomy, on the other hand, is highly effective, but it has the drawbacks of being invasive, requiring hospitalization, usually involving an additional fundoplication procedure to minimize the chances of postoperative GER, and running the risk of intraoperative esophageal perforation.

When it comes to POEM, the minimally invasive nature of the procedure, the short hospital stay needed with it, and its durable therapeutic benefits have contributed to its wide adoption as a viable alternative to standard treatments.^[12-16] In our study, 96% of patients achieved our predefined criteria of clinical success, which is comparable with the previous reports. For instance, Inoue *et al.*^[14] reported 91.3% success rates at 2 months. Similar results were published by Li *et al.*^[15] who presented the POEM experience at a single center from China, and showed success rates of 91%. Although our study had a relatively short follow-up (3 months), the durability of POEM's therapeutic benefits has been shown in numerous publications. For example, a 2013 prospective study with 12-month follow-up has shown a sustained success rate of 82.4%. Furthermore, both Li *et al.*^[15] and Nabi *et al.*^[13] reported >90% durable clinical results in the first 3 years after the procedure. Meanwhile, Li *et al.*^[15] extended their follow-up for up to 5 years and showed sustained results of >85% in the fourth and fifth years.

Complex achalasia patients were not lacking in our series. In total, 37% of our patients had prior interventions, with 35% having previous PD procedures and 4.5% having prior surgical myotomies. Our findings suggest that POEM is safe and effective even in cases with previous treatment failures. These findings are in line with the other studies like those of Nabi *et al.*^[13] Li *et al.*^[15] and Rai *et al.*^[5] whose series were >30% composed of patients who had previous treatments. In another large series that compared treatment-naïve with treatment-experienced patients undergoing POEM, success rates were 81.1% and 76.3% at 3 years, respectively, with similar safety results.^[17] Interestingly, overall complications and treatment failures are reported to be higher in treatment-experienced patients undergoing surgical myotomy.^[18]

In terms of adverse events, most of those found in our series were self-limiting and did not require prolongation of hospital admission, with pneumoperitoneum being the most commonly reported one. In a 2015 meta-analysis of 1,045 patients, complications that were commonly reported were subcutaneous/mediastinal emphysema, pneumothorax, pneumoperitoneum, pleural effusion, and aspiration pneumonia.^[4] Although the overall number of adverse events appeared to be higher with POEM than with other procedures, most of them were self-limiting or could be treated conservatively. In line with our findings, the rate of serious or life-threatening complications found in that review was low, and no deaths were associated with the procedure.

Given that there is no anti-reflux intervention in POEM, GER and reflux esophagitis (RE) are common concerns after the procedure. In our study, GER was seen in around 30% of patients after 3 months, which is higher than what was reported in previous studies. In the above meta-analysis,^[4] GER was seen in 10.9% after POEM, which was comparable with what was reported with LHM. Some of the individual studies in that review, nonetheless, had a high rate of GER, but like in our study, could be managed effectively with PPIs. The results of these studies are more consistent with recent literature, which reports higher rates of GER and RE with POEM.^[5,16]

Perhaps the most compelling question regarding the effectiveness of POEM is how it compares directly with the standard therapeutic procedures. To date, the majority of the evidence is driven from retrospective studies or prospective, uncontrolled case series like ours. Randomized comparisons between POEM and LHM were attempted in the recent literature with statistical power and long periods of follow-up (24 months), supporting POEM's

noninferiority to LHM, favoring POEM in terms of serious adverse events, and favoring LHM in terms of incidence of GER or RE.^[16] However, data are still needed to draw conclusions on how it compares with other endoscopic measures (e.g., PD) in terms of safety, efficacy, and cost-effectiveness.

In conclusion, POEM is a safe and effective procedure for the treatment of achalasia. Our experience with the procedure supports the results of previous studies that report >90% clinical success rate, short hospital stay, and a reassuring profile of adverse events.

Financial support and sponsorship

Nil.

Conflicts of interest

There are no conflicts of interest.

REFERENCES

- Boeckstaens GE, Zaninotto G, Richter JE. Achalasia. *Lancet* 2014;383:83-93.
- Sadowski DC, Ackah F, Jiang B, Svenson LW. Achalasia: Incidence, prevalence and survival. A population-based study. *Neurogastroenterol Motil* 2010;22:e256-61.
- Samo S, Carlson DA, Gregory DL, Gawe SH, Pandolfino JE, Kahrlas PJ. Incidence and prevalence of achalasia in central Chicago, 2004-2014, since the widespread use of high-resolution manometry. *Clin Gastroenterol Hepatol* 2017;15:366-73.
- Talukdar R, Inoue H, Nageshwar Reddy D. Efficacy of peroral endoscopic myotomy (POEM) in the treatment of achalasia: A systematic review and meta-analysis. *Surg Endosc* 2015;29:3030-46.
- Rai M, Woo M, Bechara R. The Canadian POEM experience: The first 50 patients. *J Can Assoc Gastroenterol* 2020;4:110-14.
- Bredenoord AJ, Rösch T, Fockens P. Peroral endoscopic myotomy for achalasia. *Neurogastroenterol Motil* 2014;26:3-12.
- Inoue H, Minami H, Kobayashi Y, Sato Y, Kaga M, Suzuki M, et al. Peroral endoscopic myotomy (POEM) for esophageal achalasia. *Endoscopy* 2010;42:265-71.
- Mu D, Li YY, Zhang MM, Zhang Y, Li Z, Li YQ. POEM for special patient cohorts: A review. *J Dig Dis* 2017;18:265-72.
- Eckardt VF, Aigner C, Bernhard G. Predictors of outcome in patients with achalasia treated by pneumatic dilation. *Gastroenterology* 1992;103:1732-8.
- Common Terminology Criteria for Adverse Events (CTCAE). Ctep.cancer.gov. https://ctep.cancer.gov/protocoldevelopment/electronic_applications/ctc.htm#ctc_50. Published 2017. [Last accessed 2020 Dec 21].
- Ortega JA, Madureri V, Perez L. Endoscopic myotomy in the treatment of achalasia. *Gastrointest Endosc* 1980;26:8-10.
- Von Renteln D, Fuchs K-H, Fockens P, Bauerfeind P, Vassiliou MC, Werner YB, et al. Peroral endoscopic myotomy for the treatment of achalasia: An international prospective multicenter study. *Gastroenterology* 2013;145:309-11.e1-3.
- Nabi Z, Ramchandani M, Chavan R, Kalapala R, Darisetty S, Rao GV, et al. Per-oral endoscopic myotomy for achalasia cardia: Outcomes in over 400 consecutive patients. *Endosc Int Open* 2017;5:E331-9.
- Inoue H, Sato H, Ikeda H, Onimaru M, Sato C, Minami H, et al. Per-oral endoscopic myotomy: A series of 500 patients. *J Am Coll Surg* 2015;221:256-64.
- Li QL, Wu QN, Zhang XC, Xu MD, Zhang W, Chen SY, et al. Outcomes of per-oral endoscopic myotomy for treatment of esophageal achalasia with a median follow-up of 49 months. *Gastrointest Endosc* 2018;87:1405-12.e3.
- Werner Y, Hakanson B, Martinek J, Repici A, von Rahden BHA, Bredenoord AJ, et al. Endoscopic or surgical myotomy in patients with idiopathic Achalasia. *N Engl J Med* 2019;381:2219-29.
- Nabi Z, Ramchandani M, Chavan R, Tandan M, Kalapala R, Darisetty S, et al. Peroral endoscopic myotomy in treatment-naïve achalasia patients versus prior treatment failure cases. *Endoscopy* 2018;50:358-70.
- Smith CD, Stival A, Howell DL, Swafford V. Endoscopic therapy for achalasia before Heller myotomy results in worse outcomes than heller myotomy alone. *Ann Surg* 2006;243:579-86.